

## Massive Elevation of CA-125 in Chylous Ascites

Tuğçe Merve Orbay<sup>1</sup>, Serdar Moraloğlu<sup>1</sup>, Nevzat Aykut Bayrak<sup>2</sup>, Ayşenur Celayir<sup>1</sup>

<sup>1</sup>Department of Pediatric Surgery, Zeynep Kamil Women and Children's Diseases Health Training and Research Center, University of Health Sciences, İstanbul, Turkey

<sup>2</sup>Department of Pediatric Gastroenterology, Zeynep Kamil Women and Children's Diseases Health Training and Research Center, University of Health Sciences, İstanbul, Turkey

Chylous ascites is a rare condition in children characterized by leakage of triglycerides and low density lipoprotein (LDL)-rich lymphatic fluid into the peritoneal cavity. Primary chylous disorders are most frequently caused by congenital lymphatic dysplasias or lymphatic malformations. In the treatment strategy, it is essential to first drain the fluid with recurrent paracentesis, stop enteral nutrition, and start parenteral nutrition and then continue the nutrition with foods containing medium-chain fatty acids.<sup>1,2</sup> CA-125 is a high-molecular-weight glycoprotein, originating from the coelomic epithelium. It is elevated in the majority of patients with epithelial ovarian cancer. It has also been shown to be elevated in lymphoma, leukemia, and gastrointestinal system malignancies.<sup>3-5</sup> In this paper, it was aimed to present a child with isolated chylous ascites and CA-125 elevation without any malignancy or additional disease.

A newborn female patient was consulted -due to antenatally diagnosed intra-abdominal ascites and right ovarian cyst. The patient was asymptomatic and her physical examination was normal. Ultrasonography of the abdomen (Figure 1) on the second day of life showed a complex lesion of 16 × 15 mm in size with echogenic walls, microcystic structures, and echogenic areas in the right ovarian region and 11 mm free fluid in the pelvis. The serum CA-125 value was 94 U/mL.

On the postnatal 18th day, diameters of the right ovarian cyst were measured as 9 × 8 mm by ultrasonography, and the cyst had dense contents. The serum CA-125 value decreased to 79.4 U/mL. In the follow-ups up to the postnatal seventh month, minimal free fluid in the abdomen was detected by ultrasonography, and the patient did not have any active complaints. Thereafter, the patient did not come for regular follow-ups.

The patient was admitted at the age of 17 months with abdominal swelling that had persisted for 6 weeks. On the physical examination, abdomen was severely distended, genitalia and perineum were normal, and there was no lymphadenopathy. In the abdominal ultrasonography, 8 cm of fluid with dense contents and septations was detected. There were massive diffuse ascites on abdominal computed tomography and no mass was observed in the abdomen or pelvic region. CA-125 value was 1845 U/mL. The patient was hospitalized and a percutaneous peritoneal catheter was inserted after paracentesis, and the fluid was drained which was milky (Figure 2). In the examination of the milky fluid, triglyceride and LDL cholesterol values were 1311 mg/dL and 183 mg/dL, respectively. Diagnosis of chylous ascites was confirmed with these findings.

Peripheral smear was performed for hematological malignancies and it was normal. After 15 days of total parenteral nutrition, feeding with medium-chain fatty-acid-containing formula was started. During the 6 weeks of in-patient observation, abdominal distension regressed and fluid drainage steadily decreased. At the end of the hospitalization period, the serum CA-125 value decreased to 383 U/mL. On the first month of the outpatient follow-up, there was no abdominal distention and ultrasonographic findings were normal. Lymphedema of the right foot was detected. She had positive family history of lower-extremity lymphedema

### Corresponding author:

Tuğçe Merve Orbay  
✉ orbaymerve@gmail.com

Received: January 22, 2023

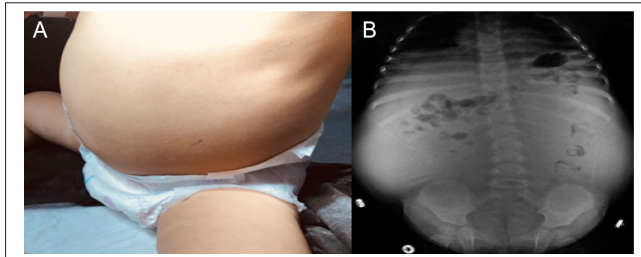
Accepted: March 16, 2023

Publication Date: July 11, 2023

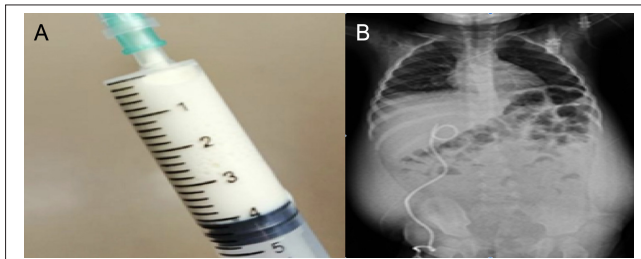
Content of this journal is licensed under a Creative Commons Attribution-NonCommercial 4.0 International License.



**Cite this article as:** Orbay TM, Moraloğlu S, Bayrak NA, Celayir A. Massive elevation of CA-125 in chylous ascites. *Turk Arch Pediatr.* 2023;58(5):555-556.



**Figure 1.** (A, B) Photography of the distended abdomen, abdominal x-ray of the patient.



**Figure 2.** (A, B) Milky fluid which was taken by paracentesis, abdominal x-ray on the first day after drainage.

as well. On the last follow-up when she was 3 years old, she was symptom-free and her serum CA-125 value was 29 U/mL.

CA-125 is not a specific tumor marker because it is also synthesized by other cells such as peritoneum, endometrium, fallopian tube, amniotic cells, lung, and conjunctiva. Therefore, it can be elevated in many physiological and pathological conditions. Well-known non-malignant reasons for CA-125 elevation are lung pathologies, heart failure, and cirrhosis. In these cases, mesothelial cells are stimulated by increased CA-125 synthesis. Zeilemaker et al studied the secretion pattern of mesothelial cells and reported increased secretion of CA-125 by inflammatory cytokines and stimuli (IL-1, tumor necrosis factor- $\alpha$ , lipopolysaccharides).<sup>4,6,7</sup> In 1987, Kanbe et al<sup>8</sup> detected CA-125 elevation with chylous ascites in a 30-year-old female patient with a diagnosis of pulmonary lymphangiomyomatosis. There is no pediatric case in the literature.

In our patient, the cystic lesion detected in the right ovarian region in the prenatal and early postnatal periods shrank. She was completely free of complaints, and advanced imaging was not performed. It can be speculated that this cystic lesion originated from the lymphatic system. Further evaluation and abdominal exploration were not done during medical treatment. So, etiology of chylous ascites was not elucidated completely.

No malignancy was detected in our patient to explain the high CA-125 level. No additional disease was detected that could cause CA-125 elevation (lung pathologies, heart failure, and

cirrhosis). In the case of primary chylous ascites, it can be said that there is a release of CA-125 from mesothelial cells due to the inflammatory stimulus created by the fluid in the peritoneal cavity. However, evidence-based studies are needed. CA-125 elevation in chylous ascites without any malignancy is a rare condition, and few cases have been reported in the literature. In order to tell whether CA-125 has a predictive value in the diagnosis of chylous ascites and to elucidate the pathophysiology of elevation of CA-125 in the chylous ascites, detailed studies with large case series are needed.

In conclusion, isolated chylous ascites can cause the massive elevation of CA-125 in children. By this knowledge, concern will be reduced about CA-125 elevation, unnecessary investigation of the etiology of CA-125 elevation will be prevented, and initiation of medical treatment of chylous ascites will be accelerated.

**Informed Consent:** Written informed consent was obtained from the patient's parents who agreed to take part in the study.

**Peer-review:** Externally peer-reviewed.

**Author Contributions:** Concept – S.M., T.M.O.; Design – S.M., T.M.O.; Supervision – S.M., A.C.; Resources – T.M.O., N.A.B.; Materials – T.M.O., A.C.; Data Collection and/or Processing – T.M.O., S.M.; Analysis and/or Interpretation – T.M.O., S.M.; Literature Search – T.M.O.; Writing Manuscript – T.M.O., S.M.; Critical Review – T.M.O., S.M.

**Declaration of Interests:** The authors have no conflict of interest to declare.

**Funding:** This study received no funding.

## REFERENCES

1. Campisi C, Bellini C, Eretta C, et al. Diagnosis and management of primary chylous ascites. *J Vasc Surg.* 2006;43(6):1244-1248. [CrossRef]
2. Nayir Büyüksahin HN, Emiralioğlu N, Özcan HN, et al. Evaluation of clinical findings in children with chylothorax: a descriptive study. *Turk Arch Pediatr.* 2023;58(1):28-33. [CrossRef]
3. Haglund C, Kuusela P, Roberts P, Jalanko H. Tumour marker CA 125 in patients with digestive tract malignancies. *Scand J Clin Lab Invest.* 1991;51(3):265-270. [CrossRef]
4. Miralles C, Orea M, España P, et al. Cancer antigen 125 associated with multiple benign and malignant pathologies. *Ann Surg Oncol.* 2003;10(2):150-154. [CrossRef]
5. Birgen D, Ertem U, Duru F, et al. Serum Ca 125 levels in children with acute leukemia and lymphoma. *Leuk Lymphoma.* 2005;46(8):1177-1181. [CrossRef]
6. Basaran A. CA-125 for diagnosis of acute appendicitis: new possibility for an old tumor marker. *Colorectal Dis.* 2010;12(2):155-156. [CrossRef]
7. Zeilemaker AM, Verbrugh HA, Hoyneck van Papendrecht AA, Leguit P. CA 125 secretion by peritoneal mesothelial cells. *J Clin Pathol.* 1994;47(3):263-265. [CrossRef]
8. Kanbe A, Hajiro K, Adaghi Y. Lymphangiomyomatosis associated with chylous ascites and high serum CA-125. *Jpn J Med.* 1987;2:26.