

DOI: 10.4274/tpa.721



Pulmonary hydatid cyst rupture in childhood: Presentation, diagnosis and treatment strategies

Tunç Özdemir, Ahmet Arıkan*Tepecik Education and Research Hospital, Pediatric Surgery Clinic, Izmir, Turkey*

Summary

Aim: Rupture of pulmonary hydatid cyst (HC) is a rare, yet very serious complication. The patients may present with cough and hydroptysis or with anaphylaxis and suffocation. Pediatric patients with ruptured pulmonary HC were evaluated retrospectively and therapeutical surgical and medical options were discussed.

Material and Method: Between January 1999 and June 2012, a total of 956 patients with HC had undergone surgical treatment. One hundred and ten patients with intrapleural/intrabronchial HC rupture were evaluated retrospectively. Demographics, clinical presentation, treatment strategies and complications were recorded and discussed.

Results: Ruptured HC's are manifested as cough-sputum (n=92) and massive hydroptysis (expectoration of cyst content) (n=47) in patients with pulmonary cysts. It was shown that rupture of superiorly localized cysts in lung was more likely. Two patients with ruptured pulmonary HC were admitted with suffocation. Severe anaphylactic reaction requiring cardiopulmonary resuscitation and mechanic ventilation was encountered in 9 patients (9%). Mild allergic reactions were observed in 13 patients. Simple cystostomy-drainage was the treatment of choice.

Conclusions: Hydroptysis accompanied by allergic reaction should suggest the diagnosis of ruptured pulmonary HC in pediatric patients. All thoracic hydatid cysts should be operated as soon as they are diagnosed in order to avoid complications and surgery should be as conservative as possible. Simple cystostomy-drainage is adequate during thoracotomy. Benzimidazole should be administered postoperatively to avoid recurrences. (*Turk Arch Ped* 2013; 48: 323-326)

Key words: Hydatid cyst, pediatrics, complications

Introduction

Hydatid cyst (HC) is typically asymptomatic and frequently diagnosed during investigation of another disease. If untreated, HC gradually enlarges and fistulizes into the bronchopulmonary system or pleura depending on the localization. Intrabronchial/intrapleural hydatid cyst rupture is a rare, but significant complication.

Other findings of hydatid cyst include release of antigenic material following cyst rupture independent of the localization and secondary immune response. The rate of systemic anaphylactic responses has been reported to be approximately 1% following intrapleural ruptures (1,2). Rupture of hydatid cyst may lead to severe allergic,

obstructive or infective sequela. Anaphylaxis related with cyst rupture may become a life-threatening complication.

Intrabronchial/intrapleural HC rupture requires urgent surgical intervention. Although surgical treatment is the primary treatment method, there is no consensus on prophylactic treatment and methods (3).

Although use of benzimidazole derivatives is common in patients who cannot be operated, their adjuvant use is more common for the aim of preventing recurrence in the post-operative period. Currently, they are regularly used for 10-15 days before operation in patients with rupture/fistulization. However, drug usage is not possible before operation in cases which are urgent.

Address for Correspondence/Yazışma Adresi: Tunç Özdemir MD, Tepecik Education and Research Hospital, Pediatric Surgery Clinic, Izmir, Turkey

E-mail: ozdemirtunc@yahoo.com **Received/Geliş Tarihi:** 14.01.2013 **Accepted/Kabul Tarihi:** 03.09.2013

Turkish Archives of Pediatrics, published by Galenos Publishing / Türk Pediatri Arşivi Dergisi, Galenos Yayınevi tarafından basılmıştır.

Our patient group has the highest number of patients in terms of ruptured pulmonary HC in the pediatric age group. In this report, the treatment methods we used in pediatric patients with ruptured pulmonary HC in a period of 13 years were discussed.

Material and Method

The medical records of 956 patients who were treated in our clinic because of pulmonary HC between January 1999 and June 2012 were examined retrospectively. In this time period, 110 patients who were found to have intrabronchial and/or intrapleural HC rupture and in whom surgical treatment was administered were included in the study.

In each patient, complete blood count, blood gases, serum biochemistry and indirect hemagglutination test for *ecchinococcus* were performed. An indirect hemagglutination test for *ecchinococcus* higher than 1/330 was considered positive.

In the pre-operative evaluation of the patients, lung graphy and thoracic and upper abdominal computerized tomography (CT) were performed after a detailed physical examination in all patients. Abdominal USG was performed in all patients because of the possibility of accompanying abdominal HC.

Chest tube was placed primarily in patients who were found to have pneumothorax and/or pleural effusion. Simple cystotomy-drainage method was applied surgically by opening the posterior rib cage. Cyst walls were also excised, if they were not closely related with functional lung tissue. Bronchial fistulae observed during opening the rib cage were closed. If not performed before, intercostal tube was placed during the process of surgery and connected with closed under-water drainage. This tube was removed a few days later.

Benzimidazole derivatives which were started just before the operation were continued to prevent recurrence after the operation.

Age, gender, complaints at presentation, physical examination findings, cyst properties, imaging results, components which caused to a tendency to rupture and the disease were evaluated. The mean follow-up time after operation was 21 months (6-36 months).

Results

The mean age of the patients was 9,2 (4-14 y) years. While the number of male patients was 64 (5%9), the number of female patients was 46 (41%). Complaints which led to referral to hospital are shown in Table 1.

Cough and sputum are the most common symptoms and their diagnostic values are low. The most common physical finding was found to be decreased respiratory sounds in the involved hemithorax. In 47 patients, a history of severe hydroptysis (emptying of the cyst content from the trachea by cough) which is the strongest finding of rupture of the cyst to the airway was present. Expectoration of the cystic

wall or vesicle cysts was not observed in any patient. Two patients presented to the emergency department with a picture of suffocation and agony because of aspiration of the cyst content.

Pneumothorax was not observed in the patients in whom the cyst was opened only into the airway. In these patients, the typical radiological appearance is air-fluid level in the cyst. Pleural effusion was found in 29 patients with ruptured cyst in the pleural space in our patient group. In 20 patients, the cyst opened both into the airway and pleural space. Pneumothorax was found in 17 of 20 patients (15% of allpatients) who had ruptured cyst both in the airway and pleural space. Intercostal tube drainage was administered in the patients with pneumothorax and/or pleural effusion as soon as the diagnosis was made. These patients were operated following tube drainage. Intercostal tube drainage was continued for a mean period of 7 days (3 days-3 weeks).

Allergic reaction was a common finding which affected 22 patients (20%). Mild allergic reactions characterized with cutaneous lesions (n:4) and mild laryngeal edema (n:9) were treated with antihistaminic and corticosteroid administration. Severe anaphylactic reaction which required cardiopulmonary resuscitation and mechanical ventilation developed in 9 patients (8%).

Giant cystic mass containing a single "air-fluid level" on plain lung graphy was diagnostic for HC rupture in the airway (Figure 1,2). Again, "air bubble" on CT was observed in some of our patients (Figure 3) (4).

During assessment of our patients, hepatic HC was found in 25 patients additionally on abdominal USG (23%). All of these patients were subsequently operated for this reason.

15 of the patients were serologically negative (14%).

Age was not observed to be a factor which caused to tendency to cyst rupture ($p>0.05$). However, extraordinary localization was found to be a more significant factor which caused to tendency to cyst rupture compared to regular localization ($p<0.05$). Large cysts (≥ 8 cm) were found to tend to rupture with a higher rate ($p<0.05$). No significant difference was found between genders in terms of cyst rupture ($p=0.95$).

Cystotomy-drainage method was applied in all patients.

Table 1. General complaints in ruptured pulmonary hydatid cyst

Complaint	Number of patients
Severe hydroptysis	47
Cough-sputum	92
Dyspnea	46
Anaphylaxis	9
Pneumothorax	17
Pleural effusion	29
Suffocation	2
Total	110

Bronchial fistulae which could be observed were repaired. Scolicidal agents were not used in ruptured cysts because of the risk of chemical damage. Excision of functional lung tissue was not performed in any of the patients. Capitonage was not performed in any patient.

Intercostal tube drainage was prolonged in 4 patients because of bronchial fistula. In these patients, the fistula was closed spontaneously in a mean period of 2 weeks and no additional surgical intervention was needed. Wound infection was not observed in any patient and no patient was lost.

Discussion

Hydatid cyst occurs in the liver with a rate of 50-79% and in the lung with a rate of 10-30%. Cyst rupture may occur spontaneously or because of trauma (5). When hydatid cyst ruptures, it is named as complicated cyst and the picture at presentation may substantially vary according to the nature of rupture (6). Echinococcal cysts always carry the risk of rupture and anaphylactic reaction. In addition to anaphylactic reaction, there is a risk of dissemination of echinococcal scolices and daughter cysts to the healthy viscera.

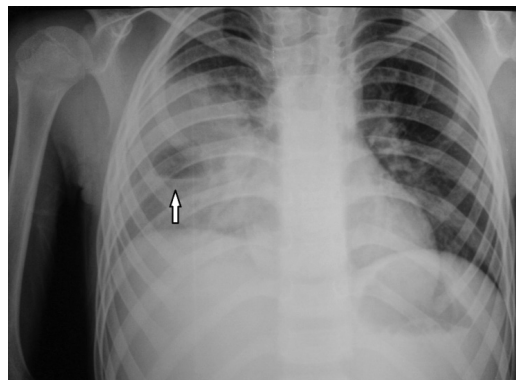
Although the diagnosis can be made by lung graphy, thoracic CT is needed in some cases. CT may be required to evaluate the internal structure of the cyst and for accurate localization (4). Negative serology does not exclude the diagnosis of hydatid disease (7). Seronegativity may be present with a rate of 3-40% especially in hydatidosis cases involving the lung (8). In our patient group, 15 patients were seronegative.

Allergic complaints may be observed in the form of urticaria or macular rash in the skin. Sometimes, anaphylaxis which is a severe and life-threatening condition may also develop. Anaphylactic reaction developed in 9 patients in our study and mild allergic findings occurred in 13 patients.

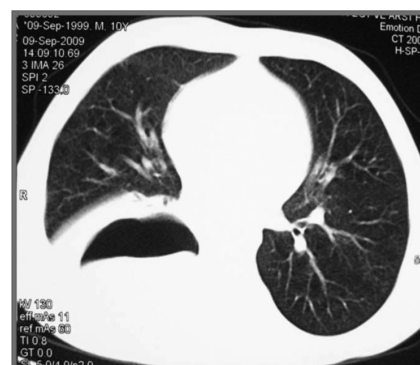Different rates have been reported for HC rupture in the literature (2.4-6.2%). Empyema has been reported with a rate of 7.6% in pulmonary HC cases (6). It can be stated that cysts localized in the apex of the lung grow faster and tend to rupture with a higher rate ($p<0.05$). Again, it has been shown that cysts with a diameter above 8 cm have a tendency to intrabronchial/intrapleural rupture with a higher rate ($p<0.05$). No significant relation was found between HC rupture and age and gender.

In hydatid disease, surgical treatment should be the first-choice treatment. Enucleation is not possible in ruptured cysts. Although methods which protect the parenchyma are preferred primarily, the necessity of large pulmonary resections in cases of pulmonary HC is still controversial (9). In our patient group, cystotomy-drainage technique could be applied in all patients without any problem. The parts of the cyst which were not surrounded by the lung parenchyma were excised as much as possible, but resection of healthy lung tissue was avoided even if adjacency with the cyst wall was present for the aim of protecting lung function as much

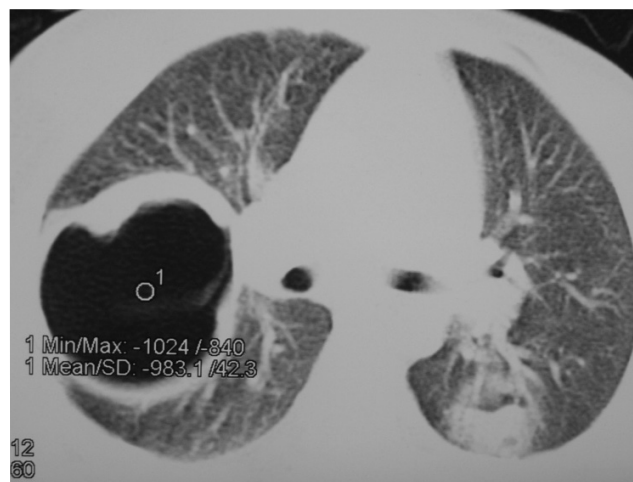
as possible. It is generally accepted that the most important factor in management of pericystic cavity is closure of patent bronchial openings. Therefore, bronchial openings which could be observed in our patients were carefully closed. Nevertheless, bronchopleural fistula which required prolonged intercostal drainage developed in 4 patients.



Picture 1. Lung graphy in ruptured pulmonary hydatid cyst. Air-fluid level in the right hemothorax



Picture 2. CT appearance in ruptured pulmonary hydatid cyst



Picture 3. “Air bubble” appearance in ruptured pulmonary hydatid cyst

As Erdoğan et al. (10) reported before, capitonage is not necessary in treatment of pulmonary HC. Capitonage was not performed in the lung tissue in any of our patients.

Resection of lung tissue should be avoided in patients with pulmonary HC. Lobectomy is not recommended even in patients with lobar infection, multiple cysts, giant cysts and atelectasis (11). Since the lung tissue compressed is generally intact, it re-expands after operation (12). In addition, there is a risk of recurrence in HC disease. Therefore, protection of lung parenchyma as much as possible is the golden rule in surgical treatment of pulmonary HC.

Use of scolical agents including hypertonic saline solutions (15-30%) is not recommended, since it may lead to problems including escape of hypertonic solution into the airway. Following excision of the cyst membrane, washing the cyst cavity with povidon iodide reconstituted with serum physiologic is sufficient.

Although there is no sufficient number of studies related with preoperative use of benzimidazol derivatives (13), it is generally accepted that preoperative use of these substances for 7-14 days is efficient. In our clinic, benzimidazol derivatives are preoperatively administered for 7-10 days in uncomplicated HC patients. However, benzimidazol derivatives which cannot be given for a while preoperatively in patients with ruptured HC patients were started as soon as the diagnosis was made and were continued postoperatively for 6 months with monitoring of liver function tests. No recurrence of pulmonary HC was observed in any patient in the long-term follow-up.

Conclusion

All patients with pulmonary HC should be operated as soon as the diagnosis is made to prevent complications. In patients who present with pneumothorax and/or pleural effusion, intercostal drainage should be performed urgently and primarily.

Anaphylactic reactions are more rare than expected, but may be fatal. Antiallergic treatment may be rarely needed in mild allergic conditions. The prophylactic activity of benzimidazol derivatives is considerably high. Adjuvant treatment should also be administered postoperatively to

prevent recurrence.

Conflict of interest: None declared.

References

1. Magistrelli P, Masetti R, Coppola R, Messina A, Nuzzo G, Picciocchi A. Surgical treatment of hydatid disease of the liver. A 20-year experience. *Arch Surg* 1991; 126: 518-522.
2. Karavias DD, Vagianos CE, Kakkos SK, Panagopoulos CM, Androulakis JA. Peritoneal echinococcosis. *World J Surg* 1996; 20: 337-340.
3. Sivriköz MC, Tunçözgür B, Nacak I, Elbeyli L. Surgical treatment of pulmonary hydatid cysts in pediatric patients. *Pediatr Pulmonol* 2003; 35: 87-90.
4. Erdem CZ, Erdem LO. Radiological characteristics of pulmonary hydatid disease in children: less common radiological appearances. *Eur J Radiol* 2003; 45: 123-128.
5. Aribas OK, Kanat F, Gormus N, Turk E. Pleural complications of hydatid disease. *J Thorac Cardiovasc Surg* 2002; 123: 492-497.
6. Kuzucu A, Soysal O, Ozgel M, Yologlu S. Complicated hydatid cysts of the lung: clinical and therapeutic issues. *Ann Thorac Surg* 2004; 77: 1200-1204.
7. Tor M, Ozvaran K, Ersoy Y, Senol T, Altuntas N, Kiliçoglu G, Celik L. Pitfalls in the diagnosis of complicated pulmonary hydatid disease. *Respir Med* 2001; 95: 237-239.
8. Gadea I, Ayala G, Diago MT, Cuñat A, de Lomas JG. Immunological diagnosis of human cystic echinococcosis: utility of discriminant analysis applied to the enzyme-linked immunoelectrotransfer blot. *Clin Diagn Lab Immunol* 1999; 6: 504-508.
9. Hasdiraz L, Oğuzkaya F, Bilgin M. Is lobectomy necessary in the treatment of pulmonary hydatid cysts? *ANZ J Surg* 2006; 76: 488-490.
10. Erdogan A, Ayten A, Demircan A. Methods of surgical therapy in pulmonary hydatid disease: is capitonnage advantageous? *ANZ J Surg* 2005; 75: 992-996.
11. Karaoglanoglu N, Kurkcuoglu IC, Gorguner M, Eroglu A, Turkyilmaz A. Giant hydatid lung cysts. *Eur J Cardiothorac Surg* 2001; 19: 914-917.
12. Akcan A, Sozuer E, Akyildiz H, Ozturk A, Atalay A, Yilmaz Z. Predisposing factors and surgical outcome of complicated liver hydatid cysts. *World J Gastroenterol* 2010; 16: 3040-3048.
13. Prousalidis J, Kosmidis C, Anthimidis G, Fachantidis E, Harlaftis N, Aletras H. Forty-four years' experience (1963-2006) in the management of primarily infected hydatid cyst of the liver. *HPB (Oxford)* 2008; 10: 18-24.