



An 18-month old male infant with respiratory distress

Buket Kılıçaslan, Ünal Paltacı, İlknur Erol

Başkent University Adana Application and Research Center, Department of Pediatrics, Adana, Turkey

Case

An 18-month old male patient presented to our pediatric emergency department with swelling in the neck and dyspnea. In the history, it was learned that he had fever and swelling in the neck two weeks ago, fever was not present for the last one week, but swelling in the neck gradually increased and he had dyspnea for the last two days. He had a history of bronchiolitis in the past for two times. There was no history suggesting immune deficiency. On physical examination, his general status was poor, he had respiratory distress, tachypnea (64/min) and suprasternal retractions. He had extensively hypertrophic tonsils (grade 3-4 bilaterally). Multiple lymphadenopathies with a size of 2.5 cm were observed in bilateral neck regions. The weight and height were between the 25th and 50th percentiles.

The respiration became superficial a short time after presentation and methylprednisolone at a dose of 1 mg/kg/dose every 6 hours was administered; the patient was intubated and connected to mechanical ventilator. Thoracic and cervical computerized tomography revealed multiple lymphadenopathy, adenoid hypertrophy, obliterated respiratory airway and bilateral extensive consolidation areas; no abscess formation or foreign body was observed (Figure 1, 2). In laboratory investigations, leukocytosis (16,000/mm³) was found. Total immunoglobulin G, M and A levels were found to be normal. Throat culture remained negative. Ceftriaxone (80 mg/kg/day) was started because of presence of consolidation areas, poor general status and leukocytosis. The patient was monitored in the intubated state for 48 hours. When the general status improved, the patient was extubated and his treatment was continued.

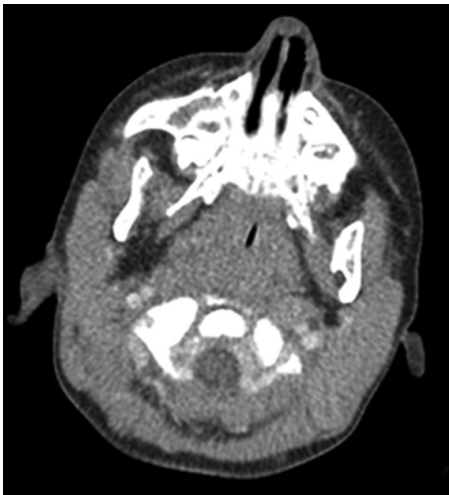

Figure 1. Obliterated air column due to adenoid hypertrophy in the neck

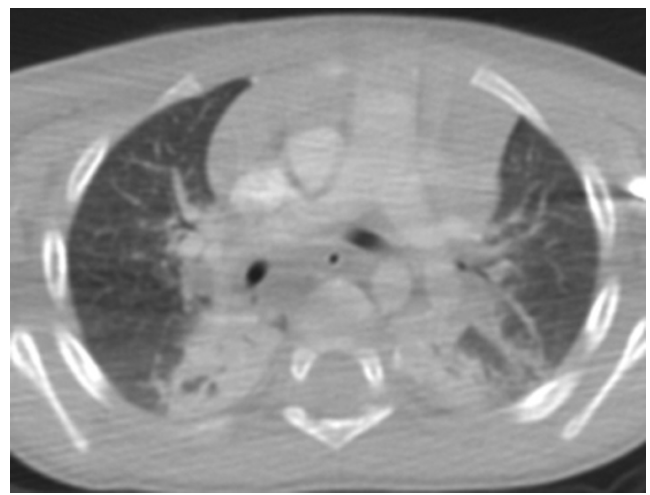


Figure 2. Extensive areas of consolidation in the lung

Address for Correspondence/Yazışma Adresi: Buket Kılıçaslan MD, Başkent University Adana Application and Research Center, Department of Pediatrics, Adana, Turkey

E-mail: drbuket73@yahoo.com **Received/Geliş Tarihi:** 05.07.2013 **Accepted/Kabul Tarihi:** 29.08.2013

Turkish Archives of Pediatrics, published by Galenos Publishing / Türk Pediatri Arşivi Dergisi, Galenos Yayınevi tarafından basılmıştır.

Systemic steroid treatment was completed to 3 days and parenteral antibiotic treatment was completed to 10 days. The necessary tests were performed for a definite diagnosis.

Diagnosis: infectious mononucleosis

Leukocytosis (16,000/mm³), lymphocytosis (72%) and monocytosis (30%) were found in the blood. In the follow-up of the patient, EBV-IgM (VCA p19) was found to be ++ and EBV-IgG (VCA p19) was found to be +++. After the patient was discharged, he was evaluated in our otolaryngology clinic and tonsilloadenoidectomy was performed.

Discussion

Infectious mononucleosis (EMN) is a generally benign, self-limiting clinical picture which is caused by Epstein-Barr virus (EBV). Infections related with this virus usually develop in childhood and are asymptomatic below the age of 2 years. They do not cause to epidemics and are accepted to be mildly contagious. Although the most common clinical findings of infectious mononucleosis are fever, cervical lymphadenopathy and tonsillopharyngitis, upper respiratory tract obstruction is a rare complication (1,2).

It is transmitted by close contact with saliva and throat secretions and blood and contagious materials. The incubation time is 10-14 days in children. The time and severity of the disease may be very variable (3). Fever (95%), lymphadenopathy (94%), tonsillopharyngitis (70%), splenomegaly (50%), hepatomegaly (10-15%), palatal petechiae (25-60%) and less commonly jaundice, rash and periorbital edema constitute the clinical picture of infectious mononucleosis (2,3). Although our patient was below the age of 2 years, he presented with severe respiratory distress. In the history a picture of fever, lymphadenopathy and tonsillitis was present.

In infectious mononucleosis, leukopenia, normal leukocyte count, lymphomonocytosis and 30% Downey cells (from the second week) may be observed. Serologically, EBV-VCA-IgM and IgG positivity in the 2nd-3rd week is diagnostic for primary infection (3). Streptococcal tonsillitis may be observed in 10-19% of the patients in association (4). In our patient, the diagnosis was made with presence of lymphomonocytosis and positivity of serological tests.

Infectious mononucleosis is a self-limiting disease, but upper respiratory tract obstruction, pneumonia, pleural effusion and hilar lymphadenopathy are rare respiratory complications. Although the picture of pneumonia in our patient might be related with Epstein-Barr virus, it was thought that it would be appropriate to continue parenteral antibiotic treatment because of presence of poor general status, leukocytosis and possibility of bacterial co-infection. Use of corticosteroids in infectious mononucleosis is indicated in presence of upper respiratory tract obstruction, autoimmune hemolytic anemia, neutropenia,

thrombocytopenia associated with hemorrhagia, meningoencephalitis and other neurological complications. Parenteral dexamethasone and oral methylprednisolone are among the recommended therapies. It has been reported that dramatic results are obtained in 24-72 hours (2,5). Compatible with the literature information, we also administered parenteral methylprednisolone in our patient for 72 hours. Severe EMN picture usually shows presence of underlying immune deficiency (5). However, our patient had no immune deficiency. The rate of upper respiratory tract obstruction in patients with a diagnosis of acute EMN has been reported to be 1-3.5% (6,7). Wohl et al. (2) found upper respiratory tract obstruction in 11 of 36 patients with a diagnosis of infectious mononucleosis and reported that endotracheal intubation was performed in a single patient who was four years old. Lobo et al. (8) intervened to a case of upper respiratory tract obstruction secondary to infectious mononucleosis who presented with retropharyngeal abscess with endotracheal intubation. Salazard et al. (9) found respiratory tract infection related with infectious mononucleosis in a 9-year old patient and found it necessary to perform endotracheal intubation. Mortality is observed rarely; neurological complications, spleen rupture and upper respiratory tract obstruction are among the most common causes of mortality in infectious mononucleosis (5). Our patient was discharged with cure after early endotracheal intubation and corticosteroid treatment.

Conclusively, this patient was presented to draw attention to the fact that Epstein-Barr virus may be manifested with rare but fatal complications including acute upper respiratory tract obstruction in children below the age of 2 years.

References

1. Sumaya CV, Ench Y. Epstein-Barr Virüs infections, mononucleosis in children, I and II. *Pediatrics* 1985; 75: 1003-1018.
2. Wohl DL, Isaacson JE. Airway obstruction in children with infectious mononucleosis. *Ear Nose Throat J* 1995; 74: 630-638.
3. Vardar F. EBV. *Güncel Pediatri* 2008; 3: 62-65.
4. Snyderman NL, Stool SE. Management of airway obstruction in children with infectious mononucleosis. *Otolaryngol Head Neck Surg* 1982; 90: 168-170.
5. Jenson HB. Acute complications of Epstein-Barr virus infectious mononucleosis. *Curr Opin Pediatr* 2000; 12: 263-8.
6. Johnsen T, Katholm M, Stangerup SE. Otolaryngological complications in infectious mononucleosis. *J Laryngol Otol* 1984; 98: 999-1001.
7. Woolf DC, Diedericks RJ. Airway obstruction in infectious mononucleosis. A case report. *S Afr Med J* 1989; 75: 584-585.
8. Lobo S, Williams H, Singh V. Massive retropharyngeal lymphadenopathy in an infant: an unusual presentation of infectious mononucleosis. *J Laryngol Otol* 2004; 118: 983-984.
9. Salazard B, Paut O, Nicollas R, Zandotti C, Chrestian MA, Thuret I, Camboulives J. Severe upper airway obstruction in infectious mononucleosis: a life emergency. *Arch Pediatr* 2001; 8: 952-956.