



Evaluation of cardiac functions of infants of diabetic mothers using tissue Doppler echocardiography

Derya Çimen¹, Sevim Karaaslan²

¹Department of Pediatrics, Selçuk University Faculty of Medicine, Konya, Turkey

²Department of Pediatrics, Division of Pediatric Cardiology, Necmettin Erbakan University Faculty of Medicine, Konya, Turkey

Abstract

Aim: Transient cardiac hypertrophy occurs in infants of diabetic mothers. The effect of this state on cardiac functions was investigated with a case-control study using tissue Doppler technique.

Material and Methods: In this study, right and left ventricle systolic and diastolic functions of 45 term babies of diabetic mothers and 50 healthy term newborns were examined using tissue Doppler echocardiography.

Results: The septum was found to be thick in 16 (36%) of the babies of diabetic mothers. Both the left and right ventricle myocardial velocities were found to be lower in the babies of diabetic mothers compared to the control group. In our study, the Em/Am ratio was found to be below one only in the babies of diabetic mothers in the left ventricle in contrast to the control group. In addition, the Em/Am ratio in the septum and right ventricle was found to be below one both in the babies of diabetic mothers (group 1, 2) and control group. The calculated Tei index was found to be higher in the babies of diabetic mothers who had a thicker interventricular septum compared to the control group.

Conclusion: Interventricular septal thickening in babies of diabetic mothers disrupt the diastolic function of both ventricles. This can be demonstrated by tissue Doppler echocardiography. These results show that diastolic function is disrupted in both ventricles in babies of diabetic mothers and only in the right ventricle in healthy babies. It was thought that this could be explained by right ventricular dysfunction arising from physiological pulmonary hypertension in the neonatal period. Subclinical right and left ventricular diastolic dysfunctions which we found by tissue Doppler indicate that babies of diabetic mothers especially with a thick septum should be closely monitored. (Türk Ped Arş 2014; 49: 25-9)

Key words: Infant of diabetic mother, tissue Doppler echocardiography, cardiac functions

Introduction

Diabetes in the mother is a condition which leads to difficulty in the fetus with significant congenital disorders, risk of premature delivery and increased prenatal morbidity and mortality (1). In addition, it causes to neonatal hypoglycemia, macrosomy and transient myocardial hypertrophy which regresses in the postnatal 2-4 weeks (2). Increased insulin in the fetus and newborn may lead to disproportional septum thickening, left ventricular outlet stenosis, transient hypertrophic subaortic stenosis and heart failure in babies of diabetic mothers (3, 4). Systolic and diastolic functions of the heart in infants of diabetic mothers (IDMs) have been studied by traditional echocardiography, but there is a limited number of studies conducted with tissue Doppler echocardiography. The aim of our study was to determine cardiac dysfunction by comparing tissue Doppler echocardiography results of term babies born by normal vaginal delivery and babies of diabetic mothers.

Material and Methods

Study groups

This study was performed between 01.01.2006 and 09.01.2008 in Selçuk University Meram Medical Faculty, Department of Pediatrics, Division of Pediatric Cardiology. The study groups were examined by tissue Doppler echocardiography in Pediatric Cardiology Echocardiography Laboratory. The patients were evaluated in the neonatal period. The study is a prospective case-control study. 16 babies of diabetic mothers (36%) who had an interventricular septum thickness greater than normal on echocardiography (group 1) and 29 babies of diabetic mothers who had a normal septum thickness (64%) (group 2) were included in the study as study groups. The

Address for Correspondence: Derya Çimen, Department of Pediatrics, Selçuk University Faculty of Medicine, Konya, Turkey.

E-mail: cimendr@hotmail.com

Received: 14.02.2013 **Accepted:** 04.07.2013

©Copyright 2014 by Turkish Pediatric Association - Available online at www.turkpediatriarsivi.com

DOI:10.5152/tpa.2014.843

control group consisted of 50 healthy babies who were born in the same hospital at the same dates at term and whose mothers were not diabetic.

The study was initiated after obtaining approval from the ethics committee of Selçuk University, Meram Medical Faculty. In addition, all parents were informed about the aim and content of the study and their consents were obtained. Patients who had congenital heart disease, dysmorphic findings, poor general status, asphyxia, prematurity, severe respiratory distress, a history of traumatic delivery and findings of intrauterine infection were excluded from the study.

Echocardiographic examination

The images were obtained with the patient in the supine position using Hewlett-Packard Sonos 5500 (Hewlett-Packard Co, Andover, Massachusetts) ultrasonography system. Tissue Dopple imaging methods were applied using 5-12 mHz probes according to the method described by Isaaz et al. (5). On apical four-chamber images, the lateral mitral valve for the left ventricle, lateral tricuspid valve for the right ventricle and interventricular septum were measured in the middle segment. Myocardial velocities were measured in systole (Sm), early diastole (Em) and late diastole (Am) and the Em/Am ratio was calculated. The isovolemic contraction time, contraction period and isovolemic relaxation time were measured. The Tei index was calculated using the formula (Isovolemic contraction + isovolemic relaxation time/contraction period) (Figure 1).

Statistical Analysis

The data were entered into the Statistical Package for the Social Sciences (SPSS) 13.0 package program. The variables were given as mean±standard deviation. The Oneway Anova test was used in the analysis of the data. The Tukey HSD test was used in post hoc analysis for variables which were found to be different. A p value of ≤0.05 was considered statistically significant.

Results

When the general properties of the groups were examined, there was no difference in terms of gender and gestational week. Birth weights were higher in both study groups compared to the control group (p=0.001) (Table 1).

The interventricular septum measurements obtained during diastole in the babies of diabetic mothers on M-mode echocardiographic examination are shown in Table 2. The Em, Am and Sm velocities in the right ventricle, left ventricle and septum were lower in the babies of diabetic mothers compared to the control group (p=0.001) (Table 3-5).

The ratio of Em velocity to Am velocity (Em/Am) in the right and left ventricle was lower in the babies of diabetic mothers compared to the control group (p=0.030). This ratio was found to be lower than 1 (Table 3, 5).

The left ventricular Tei index was found to be 0.50±0.11 in the babies of diabetic mothers in group 1 and 0.48±0.15 in the con-

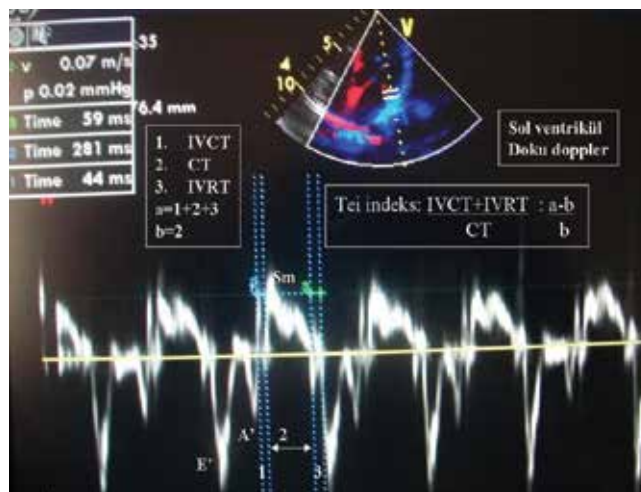


Figure 1. Calculation of Tei index on tissue Doppler echocardiography

Table 1. General properties of the patient and control groups

	Group 1 n=16	Group 2 n=29	Control n=50	p
Gender (M/F)	9/7	16/13	25/25	0.450
Birth weight (g)	4 406±743	3 553±699	3 085±256	0.001
Gestational week	38.25±0.65	38.05±0.61	39.08±0.78	0.613
p<0.05, statistically significant				

Table 2. Interventricular septum values in group 1 and group 2 infants of diabetic mothers

	IVS thickness (mm)	IVS normal value (mm)
Group 1 (n=16)	8.75±3.1	4.5-5
Group 2 (n=29)	4.22±0.7	4.5-5
IVS: interventricular septum		

trol group (p=0.019) (Table 3). The Tei index was found to be 0.51±0.13 in the right ventricle in the babies of diabetic mothers in group 1 and 0.48±0.11 in the control group (p=0.004) (Table 5). No significant difference was found between the groups in terms of the Em/Am ratio in the septum and Tei index (p>0.05) (Table 4).

Discussion

The most common cardiac pathology in babies of diabetic mothers is asymmetrical septal hypertrophy (6). There is an increased myocardial mass because of high levels of insulin in these patients and this may lead to dysfunction in diastole. Most babies of diabetic mothers may be asymptomatic despite this dysfunction (7).

Table 3. Variables obtained in the left ventricle with tissue Doppler echocardiography

	Group 1	Group 2	Control	p	*p
Em (cm/sn)	7.29±2.9	7.08±1.8	9.6±1.8	0.001	0.001
Am (cm/sn)	7.83±2.7	7.86±2.3	8.38±2.3	0.001	0.001
Sm (cm/sn)	6.13±1.8	5.84±1.5	7.43±1.49	0.001	0.001
Em/Am	0.97±0.38	0.93±0.26	1.1±0.28	0.030	0.035
Tei index	0.50±0.11	0.47±0.08	0.48±0.15	0.015	0.019

p<0.05, statistically significant

Em: early diastole; Am: late diastole; Sm: systole

Table 4. Variables obtained in the septum by tissue Doppler echocardiographic examination

	Group 1	Group 2	Control	p	*p
Em (cm/sn)	6.5±2.1	6.46±1.79	7.06±1.5	0.001	0.001
Am (cm/sn)	6.7±1.4	7.24±2.12	8.46±2.1	0.001	0.001
Sm (cm/sn)	5.5±1.3	5.7±1.49	7.1±1.1	0.001	0.001
Em/Am	0.97±0.3	0.92±0.23	0.85±0.17	0.198	-
Tei index	0.46±0.09	0.45±0.06	0.43±0.02	0.880	-

p<0.05, statistically significant

Em: early diastole; Am: late diastole; Sm: systole

On echocardiographic examination, findings including mainly asymmetrical septal hypertrophy, ventricular wall thickening and ventricular outlet obstruction may be observed. In our study, systolic and diastolic functions of the right and left ventricles of 45 babies of diabetic mothers who were being followed up in Selçuk University, Meram Medical Faculty, Neonatal Intensive Care Unit between 2006 and 2008 and 50 healthy term newborns were examined by tissue Doppler echocardiography in Selçuk University, Meram Medical Faculty, Pediatric Cardiology, Echocardiography Laboratory to examine the effect of the pathology in babies of diabetic mothers in whom septal thickening was found on echocardiography on cardiac functions.

Cooper et al. (8), found septal hypertrophy in 19 (31%) of 61 babies of diabetic mothers. Similarly, the interventricular septum thickness was found to be at the upper limit of normal in 36% (n=16) of the babies of diabetic mothers in our study (Table 2).

Nagueh et al. (9) found a significant reduction in the left ventricular Em, Am and Sm velocities in patients with hypertrophic cardiomyopathy in a study they conducted. In our study, the left ventricular, septal and right ventricular Em, Am and Sm velocities were found to be significantly lower in the babies of diabetic mothers compared to the control group. The Em, Am, Sm velocities in group 1 (increased septal thickness) and group 2 (normal septal thickness) were found to be significantly lower compared to the control group (Table 3-5).

Since Em represents myocardial tension in early diastole, the Em velocity is related with relaxation of the myocardium (diastolic function). Em is considered to be a variable which indicates ven-

tricular relaxation independent of volume load and a Em value of <8 cm/s has been reported to indicate relaxation dysfunction (10, 11). In the study performed by Mori et al. (12), the mean Em values obtained from the left ventricle, right ventricle and septum of healthy newborns on the 0th day and between the first and 7th days of life were found to be <8 cm/s (12). In our study, the mean left ventricular, right ventricular and septal Em velocity in group 1 IDMs and group 2 IDMs was found to be <8 cm/s. In our study, the right ventricular Em value was also found to be <8 cm/s in the control group. Conclusively, findings indicating relaxation dysfunction were found in both ventricles and in the septum in IDMs and in the right ventricle in the control group.

In normal adults, a Sm velocity of >5.4 cm/s in the mitral annulus indicates that ejection fraction which shows systolic function is normal (11). In our study, the Sm velocity for the left ventricle, right ventricle and septum was found to be >5.4 cm/s in the control group and IDMs groups. This tissue Doppler finding of us indicated that systolic functions were preserved in infants of diabetic mothers.

One of the early stage findings of diastolic dysfunction is significant reduction in Em and increase in Am on tissue Doppler ultrasonography (10). The indicator of this is reversal of the Em/Am ratio (lower than 1). In our study, the left ventricular Em/Am ratio was found to be lower than 1 only in IDM group in contrast to the control group. The septal and right ventricular Em/Am ratios in IDMs groups (groups 1, 2) and control group were found to be lower than 1. These results showed that diastolic dysfunction was present in both ventricles in the IDMs group and only in the right ventricle in healthy infants. This may be explained by physiological pulmonary hypertension in the neonatal period.

Table 5. Variables obtained in the right ventricle with tissue Doppler echocardiography

	Group 1	Group 2	Control	p value	*p
Em (cm/sn)	6.7±1.4	6.8±1.6	7.9±1.2	0.001	0.001
Am (cm/sn)	8.4±2.8	9.3±1.8	11.07±2.4	0.001	0.001
Sm (cm/sn)	6.6±1.84	6.9±1.3	8.1±1.6	0.001	0.001
Em/Am	0.89±0.38	0.73±0.14	0.81±0.10	0.025	0.022
Tei index	0.51±0.13	0.46±0.07	0.48±0.11	0.005	0.004

p<0.05, statistically significant

Em: early diastole; Am: late diastole; Sm: systole

Studies have reported that variables obtained in echocardiographic examinations are consistent with interventional examinations (13). The Tei index or myocardial performance index is a variable which shows systolic and diastolic functions of the left and right ventricle (14). In the initial form of Tei index, pulsed Doppler was used (15). Subsequently, it was measured using tissue Doppler. It was found that the Tei index values obtained by using tissue Doppler were compatible with the values obtained by using pulsed Doppler (14). Wei et al. (12) reported that the mean Tei index value was 0,37±0,06 in healthy babies younger than one month (16). In our study, values close to this value were obtained in the control group. The Tei index is an index which is obtained by dividing the sum of isovolemic contraction and isovolemic relaxation times to the ejection time. The left ventricular Tei index was found to be significantly higher in group 1 IDMs (0.50±0.11) compared to the control group (0.48±0.15) (p=0.019) (Table 3). No significant difference was found between the IDMs group and control group in terms of septal Tei index (Table 4). The right ventricular Tei index was found to be significantly higher in group 1 IDMs compared to the control group (p=0.004) (Table 5). In our study, the fact that the Tei index was found to be significantly higher in group 1 IDMs compared to group 2 IDMs and the control group was related with shortness of the ejection time and prolongation of isovolemic contraction value. These significant high values of the right and left ventricular Tei indexes show that left ventricular functions were also affected in addition to right ventricular dysfunction which may be observed in IDMs and which is attributed to physiological pulmonary hypertension.

Conclusion

Interventricular septal thickening found in babies of diabetic mothers will disrupt the functions of both ventricles, though transiently. The fact that this dysfunction was more significant in the IDMs group with a thick interventricular septum compared to the other study group shows that infants with this pathology should be observed more carefully.

Ethics Committee Approval: Ethics committee approval was received for this study from the ethics committee of Selçuk University Meram Faculty of Medicine (No: 2007/172).

Informed Consent: Written informed consent was obtained from patients' parents who participated in this study.

Peer-review: Externally peer-reviewed.

Author Contributions: Concept - S.K.; Design - D.Ç.; Supervision - S.K., D.Ç.; Funding - D.Ç.; Materials - D.Ç.; Data Collection and/or Processing - D.Ç.; Analysis and/or Interpretation - S.K., D.Ç.; Literature Review - D.Ç.; Writer - D.Ç.; Critical Review - S.K.

Conflict of Interest: No conflict of interest was declared by the authors.

Financial Disclosure: The authors declared that this study has received no financial support.

References

- Ballard RA. Diyabetes mellitus. In: Taeosch HW, Ballard RA, Avery ME, (eds). Diseases of the newborn. Philadelphia: WB Saunders Company, 1991; 66-71.
- Brans YW, Huff RW, Shannon DL, Hunter MA. Maternal diabetes and neonatal macrosomia. Postpartum maternal HbA1c levels and neonatal hypoglycemia. Pediatrics 1982; 70: 576-81.
- Mormile R, Vittori G, De Michele M, Squarcia U, Quaini F. Postnatal regression of hypertrophic cardiomyopathy in infants of diabetic mothers: a crosstalk between Hox genes and epidermal growth factor (EGF) gene polymorphism? Int J Cardiol 2011; 150: 340.
- Sardesai MG, Gray AA, McGrath MM, Ford SE. Fetal hypertrophic cardiomyopathy in the fetus of a woman with diabetes. Obstet Gynecol 2001; 98: 925-7.
- Isaaz K, Thompson A, Etchevenot G, Cloez JL, Brembilla B, Pernot C. Doppler echocardiographic measurement of low velocity motion of the left ventricular posterior wall. Am J Cardiol 1989; 64: 66-75.
- Deorari AK, Saxena A, Singh M, Shrivastava S. Echocardiographic assesment of infants born to diabetic mothers. Arch Dis Child 1989; 64: 721-4.
- Thomas JD, Weyman AE. Echocardiographic Doppler evaluation of left ventricular diastolic function: Physics and physiology. Circulation 1991; 84: 977-90.
- Cooper MJ, Enderlein MA, Tarnoff H, Roge CL. Asymmetric septal hypertrophy in infants of diabetic mothers. Fetal echocardiography and the impact of maternal diabetic control. Am J Dis Child 1992; 146: 226-9.
- Nagueh SF, Bachinski LL, Meyer D, et al. Tissue Doppler imaging consistently detects myocardial abnormalities in patients with hypertrophic cardiomyopathy and provides a novel means for an early diagnosis before and independently of hypertrophy. Circulation 2001; 104: 128-30.
- Ichihashi K, Sato A, Shiraishi H, Momoi M. Tissue Doppler combined with pulsed-wave Doppler echocardiography for evaluating ventricular diastolic function in normal children. Echocardiography 2011; 28: 93-6.

11. Gulati VK, Katz WE, Follansbee WP, Gorcsan J. Mitral annular descent velocity by tissue doppler echocardiography as an index of global left ventricular function. *Am J Cardiol* 1996; 77: 979-82.
12. Mori K, Nakagawa R, Nii M, et al. Pulsed wave Doppler Tissue echocardiography assessment of the long axis function of the right and left ventricles during the early neonatal period. *Heart* 2004; 90: 175-80.
13. Border WL, Michelfelder EC, Glascock BJ, et al. Color M-Mode and Doppler tissue evaluation of diastolic function in children: Simultaneous correlation with invasive indices. *J Am Soc Echocardiogr* 2003; 16: 988-94.
14. Tei C, Ling LH, Hodge DO, et al. New index of Combined systolic and diastolic myocardial performance: a simple and reproducible measure of cardiac function--a study in normals and dilated cardiomyopathy. *J Cardiol* 1995; 26: 357-66.
15. Harada K, Orino T, Yasuoka K, Tamura M, Takada G. Tissue doppler imaging of left and right ventricles in normal children. *Tohoku J Exp Med* 2000; 191: 21-9.
16. Cui W, Roberson DA. Left ventricular Tei index in children: comparison of tissue Doppler and M-mode echocardiography normal values. *J Am Soc Echocardiogr* 2006; 19: 1438-45.