



Pilomatrixoma localized in the arm and forearm

Nevzat Dabak¹, Alper Çıraklı², Bedri Kandemir³, Sevgi Çıraklı⁴, Sabit Numan Kuyubaşı²

¹Division of Orthopaedics and Traumatology, Private Medicalpark Hospital, Samsun, Turkey

²Department of Orthopaedics and Traumatology, Ondokuz Mayıs University Faculty of Medicine, Samsun, Turkey

³Division of Pathology, Private Medicalpark Hospital, Samsun, Turkey

⁴Department of Pediatrics, Ondokuz Mayıs University Faculty of Medicine, Samsun, Turkey

Abstract

Pilomatrixoma is a rare benign skin tumor arising from hair follicle stem cells which is also known as calcifying epithelioma of Malharbe. It occurs with a rate of 0.1% among skin tumors. The definite diagnosis is made histopathologically. In treatment, it is recommended that the lesion be excised surgically. In this study, we wished to present two patients who presented with swelling and underwent excisional biopsy as a result of magnetic resonance imaging and whose pathological result was reported to be pilomatrixoma in accompaniment with the literature. (Türk Ped Arş 2014; 49: 340-3)

Key words: Arm, forearm, pilomatrixoma

Introduction

Pilomatrixoma is a rare benign skin tumor arising from multidirectional cells of hair root follicles which is also known as Malharbe's calcified epithelioma (1). Malharbe and Chenantais defined the lesion as calcified epithelioma in 1880 for the first time (2, 3).

Among skin tumors, pilomatrixoma is observed with a rate of 0.1% (4). Clinically, it is frequently observed as a single, firm, red-blue mass in the skin or subcutaneous tissue. Multiple lesions may also be observed with a rate of 2-10% (4). In addition, its malign forms have been reported. In nearly 50% of the cases, the mass is observed in the head-neck region and less frequently in the trunk and extremities (4-7). Although it can be observed at any age, it is frequently observed below the age of 20 years (4, 8). It occurs more commonly in the white race and the female/male ratio is 3/2 (9). The size of the lesion generally ranges between 0.5 and 3 cm (4, 6, 9).

Although the diagnosis is clinically made before surgery with a rate of 40%, the definite diagnosis is made histopathologically (4, 10). The recommended treatment is surgical excision of the lesion (2, 4). Recurrence has been reported with a rate of 2-6% after surgery (5).

In this article, we aimed to evaluate two male patients (6 years and 11 years old) who had a mass localized in the forearm and arm and whose pathological diagnoses were reported to be pilomatrixoma in the light of the literature.

Cases

Case 1

A 6-year old male patient presented to our outpatient clinic with a mass palpable in the left arm. In the history, it was learned that the mass was painless for approximately 6 months and gradually increased in size. There was no history of trauma or discharge. Physical exami-

Address for Correspondence: Alper Çıraklı, Department of Orthopaedics and Traumatology, Ondokuz Mayıs University Faculty of Medicine, Samsun, Turkey. E-mail: alperomu@gmail.com

Received: 04.10.2012 **Accepted:** 14.12.2012

©Copyright 2014 by Turkish Pediatric Association - Available online at www.turkpediatriarsivi.com

DOI:10.5152/tpa.2014.298

nation revealed swelling and erythema in the $\frac{1}{2}$ lateral part of the left arm. On palpation, a firm, painless, mobile mass with regular borders and with a dimension of 3 x 3 cm which showed enlargement outwards from the skin was observed (Figure 1). Neuromotor and vascular examination of the patient was natural and no other systemic pathology was found. Magnetic resonance (MR) imaging revealed a homogeneous lesion with regular borders in the subcutaneous tissue (Figure 2).

No malignancy was considered, since the mass had regular borders and was localized in the subcutaneous tissue. Excisional biopsy was planned after obtaining consent from the patient. During the operation, it was observed that the mass was loosely adhered to the surrounding tissue and was firm. The mass was totally excised together with the surrounding soft tissue and skin with a safety border of 1 cm and a sample with a size of approximately 4 x 4 cm was sent for histopathological diagnosis. The incision was closed after bleeding was controlled. The patient who did not develop any problem in the follow-up was discharged with recommendations.

On pathological examination, the typical microscopic properties of pilomatrixoma were observed (Figure 3). The patient was followed up and no recurrence was observed in the one-year follow-up. Currently, the patient is healthy and attends his school.

Case 2

A 11-year old male patient presented to our outpatient clinic because of swelling and pain in the right forearm. In the history, it was learned that the mass was present for approximately one month. There was no

history of trauma or discharge. Physical examination revealed swelling and erythema in the volar surface of the right forearm. On palpation, a firm, painless, mobile mass with regular borders and with a dimension of 5 x 5 cm which showed enlargement outwards from the skin was observed. Neuromuscular and vascular examination was normal and no other systemic pathology was found. On magnetic resonance imaging, a homogeneous lesion involving the skin with regular borders was observed.

No malignancy was considered, since the mass had regular borders and was localized in the subcutaneous

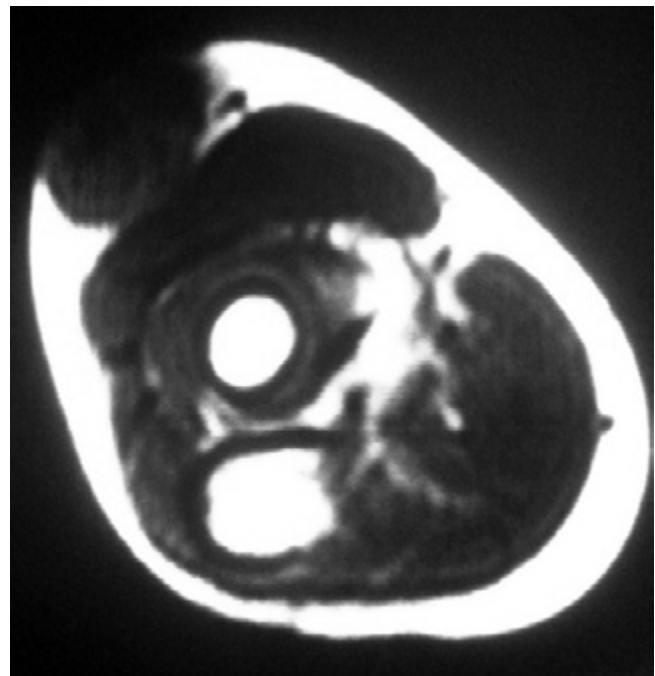


Figure 2. Magnetic resonance appearance of the subcutaneous mass with regular borders

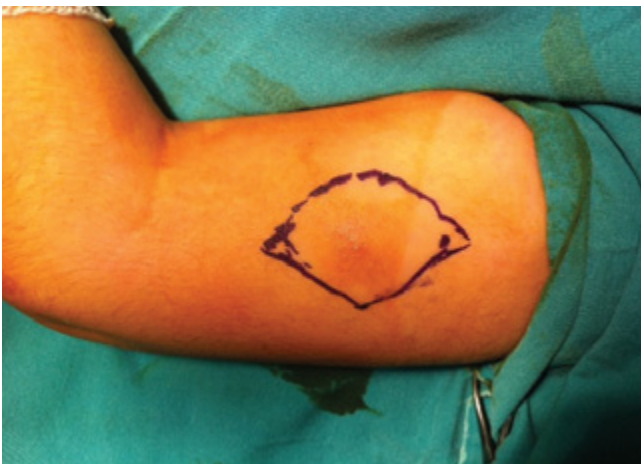

Figure 1. Preoperative appearance of the mass in the distal $\frac{1}{2}$ lateral part of the left arm

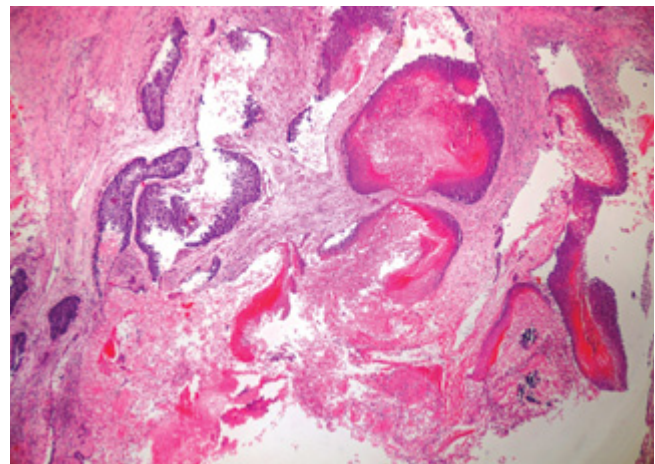


Figure 3. Typical microscopic appearance of pilomatrixoma consisting of basal cells and shadow cells (H+E x200)

tissue. Excisional biopsy was planned after obtaining consent from the patient. During the operation, it was observed that the mass was loosely adhered to the surrounding tissue and was firm. The mass was totally excised together with the surrounding soft tissue and skin with a safety border of 1 cm and a sample with a size of approximately 5 x 5 cm was sent for histopathological diagnosis. The incision was closed after bleeding was controlled. The patient who did not develop any problem in the follow-up was discharged with recommendations.

Since the pathologic diagnosis was pilomatrixoma, the patient was followed up. No recurrence was observed in the follow-up period of approximately one year. Currently, the patient is healthy and attends his school.

Discussion

Pilomatrixoma which is also known as Malharbe's calcified epithelioma currently was mentioned in 1861 in Wilcken's doctoral thesis and Malharbe and Chenantais defined the lesion as calcified epithelioma in 1880 (2, 3).

Pilomatrixoma is a rare benign skin tumor arising from multidirectional cells of hair root follicles which is frequently observed in the head-neck region. Although different causes have been proposed in the etiology, the exact cause is not known (1, 11). Recent investigations have shown that recurrent mutations in the beta-catenin gene are responsible (1). It has been reported to be related with myotonic dystrophy gene, polyoma virus, Gardner syndrome, xeroderma pigmentosum, Turner syndrome, sarcoidosis and basal cell nevus syndrome (1, 12). No sign which might be related with these conditions was found in our patients.

The lesion is generally observed below the age of 20 years (4, 8). The diagnosis is made between 5 and 15 years. It is observed more commonly in the white race and the female/male ratio is 3/2 (9). The mass is frequently observed in the head-neck region and less frequently in the trunk and extremities (4-7). Clinically, it is observed as a painless, firm and mobile mass. Multiple lesions may be observed with a rate of 2-10% (4). The lesion has a size of approximately 0.5-3 cm and is red-blue (4, 6, 9). Our patients were male and aged 6 and 11 years. The masses were firm, red and mobile. With these properties they were compatible with the literature. In one of our patients, the mass was painless which was compatible with the literature. In the other

patient, the mass was painful which was incompatible with the literature. The localizations of the masses were the forearm and arm regions which are rare localizations. They had dimensions of 3 x 3 cm and 5 x 5 cm which we considered to be borderline high. In this aspect, our patients are notable.

In the differential diagnosis, epidermal cyst, calcified lymphadenopathy, ossified or calcified hematoma, foreign body, other benign and malign soft tissue tumors should be considered (4). The primary and main method used in assessment of bone and soft tissue tumors is plain graphy. Ultrasonography (USG), computerized tomography (CT) and MRI can be used as further methods. Fine needle biopsy can be used in appropriate cases at the stage of diagnosis. There is no pathognomonic finding of pilomatrixoma, but presence of calcification may be considered in favour of pilomatrixoma (4, 5). Although the diagnosis can be made clinically before surgery with a rate of 40%, the definite diagnosis is made histopathologically (4, 10).

Treatment of pilomatrixoma is surgical excision (2, 4). Recurrence has been reported with a rate of 2-6% after surgery (5). Surgical excision was also performed in our patients. Since the mass dimensions were borderline high, the patients were included in the follow-up program and their families were informed. No recurrence was observed in the patients during the follow-up period of approximately one year.

Conclusively, pilomatrixoma can be confused with other lesions, since it occurs rarely and its characteristics are not known well (13). In this context, especially soft tissue sarcomas should be excluded in the differential diagnosis. Families should be informed of the possibility of recurrence after surgery and patients should be followed up with frequent intervals.

Informed Consent: Written informed consent was obtained from parents who participated in this case.

Peer-review: Externally peer-reviewed.

Author Contributions: Concept - N.D., A.Ç.; Design - A.Ç., S.Ç., S.N.K.; Supervision - N.D., B.K.; Funding - A.Ç., S.Ç.; Materials - A.Ç., S.Ç.; Data Collection and/or Processing - A.Ç., S.Ç., S.N.K.; Analysis and/or Interpretation - N.D., B.K.; Literature Review - N.D., A.Ç., B.K., S.Ç., S.N.K.; Writer - A.Ç., S.Ç.; Critical Review - N.D., B.K.; Other - N.D., A.Ç., B.K., S.Ç., S.N.K.

Conflict of Interest: No conflict of interest was declared by the authors.

Financial Disclosure: The authors declared that this study has received no financial support.

References

1. Kumar S. Rapidly growing pilomatrixoma on eyebrow. *Indian J Ophthalmol* 2008; 56: 83-4. [\[CrossRef\]](#)
2. Jallouli M, Yengui H, Khabir A, et al. Pilomatrixoma of earlobe. *J Cutan Aesthet Surg* 2009; 2: 36-7. [\[CrossRef\]](#)
3. Malherbe A, Chenantais J. Note sure l'epithelioma calcifie des glandes sebacees prog. *Med* 1880; 8: 826-8.
4. Demirdöver C, Sevindik M, Vayvada H, ve ark. Nadir bir lokalizasyonda dev pilomatriksoma: olgu sunumu ve litelatür derlemesi. *Türk Plastik Rekonstrüktif ve Estetik Cerrahi Dergisi* 2011; 19: 36-8.
5. Babakurban ST, Koçer NE, Erkan AN. Parotis bölgesinde pilomatriksoma: vaka sunumu. *Fırat Tıp Dergisi* 2009; 14: 224-7.
6. Pirouzmanesh A, Reinisch JF, Gonzalez-Gomez I, et al. Pilomatrixoma: a review of 346 cases. *Plast Reconstr Surg* 2003; 112: 1784-9. [\[CrossRef\]](#)
7. Yener M, Kalekoğlu N, Özdoğan A. Parotis lojunda yerleşik pilomatriksoma: olgu sunumu. *Türk Otolarengoloji Arşivi* 2002; 40: 144-7.
8. Gustin AF, Lee EY. Pilomatrixoma in a pediatric patient. *Pediatr Radiol* 2006; 36: 1113. [\[CrossRef\]](#)
9. Cigliano B, Baltogiannis N, De Marco M, et al. Pilomatrixoma in childhood: a retrospective study from Three European Paediatric Centres. *Eur J Pediatr* 2005; 164: 673-7. [\[CrossRef\]](#)
10. Forbis R, Jr Helwig EB. Pilomatrixoma (calcifying epithelioma). *Arch Dermatol* 1961; 83: 606-18. [\[CrossRef\]](#)
11. Saussez S, Mahillon V, Blaivie C, et al. Aggressive pilomatrixoma of the infra-auricular area: a case report. *Auris Nasus Larynx* 2005; 32: 407-10. [\[CrossRef\]](#)
12. Yamauchi M, Yotsuyanagi T, Saito T, et al. Three cases of giant pilomatrixoma-considerations for diagnosis and treatment of giant skin tumours with abundant inner calcification present on the upper body. *J Plast Reconstr Aesthet Surg* 2010; 63: 519-24. [\[CrossRef\]](#)
13. Külahçı Y, Sever C, Uygur F, ve ark. Pilomatriksoma: Malharbe tümörü. *Türk Plastik Rekonstrüktif ve Estetik Cerrahi Dergisi* 2009; 17: 19-24.